



Zimmer® MIS Natural-Knee® II

Surgical Technique



Longterm clinical results — new minimally invasive procedure



Zimmer® MIS Natural-Knee® II Surgical Technique

Table of Contents

System Overview	2
Design Rationale	2
Preoperative Planning	4
Patient Preparation	5
Incision and Exposure	5
Surgical Technique Summary	8
Bone Cuts	8
Preparing the Femur	9
Preparing the Tibia	10
Preparing the Patella	10
Surgical Approach	11
Locating the Medullary Canal	11
Cutting the Distal Femur	12
Drilling the Distal Femoral Holes and Calibrating the Femur	14
Finishing the Femur	15
Making the Posterior/Posterior Chamfer Cuts	17
Making the Anterior/Anterior Chamfer Cuts and the Trochlear Recess Cut	18
Preparing the Proximal Tibia	19
Using the Extramedullary Tibial Technique	19
Setting the Rotation	19
Setting the Varus/Valgus Angle of the Tibial Cut	19
Setting the Posterior Slope	20
Level of Resection	20
Cutting the Tibia	20
Sizing and Drilling the Proximal Tibia	21
Preparing the Patella	23
Trial Reduction	25
Implanting the Components	25
Pressfit Tibial Baseplate	25
Modular Cemented Tibial Baseplate	26
Tibial Insert	26
Femoral Component	26
Patella	27
Final Steps	27
Postoperative Care	27
Posterior Stabilization Option	27
Intramedullary Tibial Option	28
Using the Tibial Spacer Option	30
All-Poly Tibial Option	31
Balancing the Soft Tissue	34
Ultracongruent and Traditional Posterior Stabilized Component Indications	35

System Overview

Since 1985, the *Natural-Knee*® System has been used successfully to treat over 450,000 patients. Long-term clinical results confirm that the *Natural-Knee* System's design considerations result in improved motion and stability, and promote normal alignment and stable fixation of the implant. The mean Modified Hospital for Special Surgery knee score improved from 59.1 ± 13.2 preoperatively to 97.8 ± 4.7 postoperatively at 10-to-14 years follow-up.¹

Specific Operative Techniques

- Anatomic posterior tibial slope resections provide optimal distribution of stress on the bone structure, maximizing the load carrying capacity of cancellous bone.
- Intraoperative use of bone slurry at the bone/*Cancellous-Structured Titanium*™ (CSTi™) Porous Coating-implant interface provides up to three times the amount of bone ingrowth at the interface as compared to specimens implanted without bone slurry.^{1,2}
- Posterior-referencing femoral resection results in matched flexion and extension gaps, which help with natural rollback, natural ROM, and a potential for reduced polyethylene wear.
- Anterior-referencing option reduces the risk of anterior notching and optimizes the positioning of the extensor mechanism.
- Patellar-measured resection followed by component medialization reduces the need for lateral retinacular releases without exceeding the original patellar thickness.

Device Design

- An innovative asymmetrical tibial baseplate provides optimal coverage of the tibial plateau, creating excellent stability without impingement due to overhang, and ultimately replicating natural anatomy.
- The Ultracongruent insert provides posterior stabilization without bone sacrifice.³ This innovative design provides continuous stabilization throughout the range of motion.
- A deepened trochlear groove prevents excessive load on the patellar component while providing excellent ROM.

Material Technology

- Revolutionary CSTi Porous Coating features a cobalt-chrome femoral articulating surface combined with the biocompatibility of titanium coating, resulting in stable fixation and outstanding clinical results.^{4,5} Postmortem studies support the biocompatibility of CSTi coating and consistent bony ingrowth.¹
- Tibial baseplates are constructed from either titanium or cobalt chrome, providing surgeons a choice.

Design Rationale

Restoration of Anatomy

Surgery using the *Natural-Knee* System creates a true resurfacing by referencing the least-involved portion of the femoral condyle, the least-involved portion of the tibial plateau, and the thickest portion of the medial facet of the patella, restoring kinematics and the anatomic joint line.

Knee rotation testing and computer modeling show that the level of resection relative to the amount of bone replaced by the prosthesis on the distal femur plays an important role in knee kinematics and ligament balance.

Bone resection, followed by an equal amount of prosthetic replacement, provides the knee with near normal varus-valgus and rotational stability throughout the full range of motion.

A stepped anterior chamfer cut allows bone resection and replacement with a deeply grooved femoral component, anatomically restoring the level of the trochlear groove. As a result, patellofemoral joint stability is achieved, requiring fewer or less extensive lateral releases. In addition, the patellofemoral joint line is maintained, avoiding increased patellofemoral compressive forces.

With the *Natural-Knee* System, the tibial cut is made parallel to the joint line on the anterior/posterior plane to avoid camming or laxity during extension and flexion.⁶ Since the normal posterior tilt of the tibia is not a constant angle (range 4-12°), the tibial cut must be adjustable in order to reproduce each patient's normal posterior slope. If the posterior slope is fixed or if the tibia is cut perpendicular to the tibial shaft axis, the normal kinematics of the knee may not be simulated.

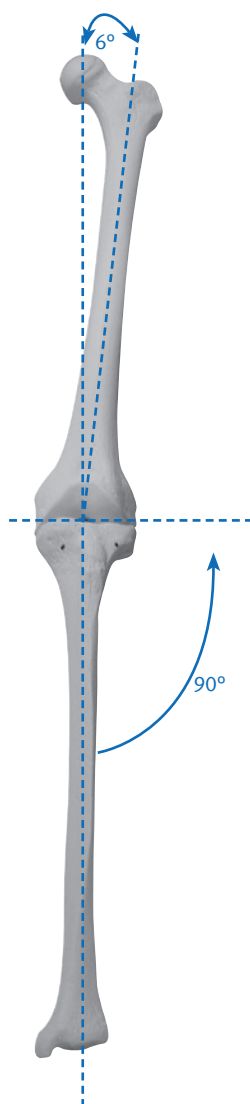
Cutting the tibia parallel to the patient's natural posterior slope may improve the load-carrying capacity of the supporting bone. Ultimate compressive strength improved 40% when bone cuts were made parallel to the joint versus perpendicular to the tibial shaft axis.⁶ If the tibial cut closely matches the anatomic posterior slope, anterior subsidence is avoided.

The proximal tibia is usually 4-5mm smaller on the lateral side than on the medial side,⁷ therefore, an asymmetric replacement provides the best coverage of the proximal tibia without soft tissue impingement. Symmetric replacements, however, require either under filling the medial side or overhanging the lateral side.

The anterior referencing option may help a valgus or revision knee, in which anatomic landmarks may be unclear.

Restoration of Normal Alignment

Normal alignment usually implies that the mechanical axis, from the center of the hip to the center of the ankle, will pass through the center of the knee. The implant should be positioned perpendicular to that line. Correct positioning is usually accomplished by cutting the tibia perpendicular or in slight varus in the frontal plane and by cutting the distal femur in 5-6° of valgus relative to the anatomic axis.



A standard 6° valgus cut of the femur is recommended for two reasons. First, the anatomic-mechanical axis angle can be measured from a radiograph, but it may be inaccurate by 1-2° because of rotational inconsistency. Second, the true anatomic axis may be off by 1-2° using intramedullary instruments if the starting point on the distal femur is too medial or lateral, or if the intramedullary rod is not perfectly centered in the medullary canal.

For marked anatomic variation (e.g., malunion), instrumentation can be used with an external alignment tower pointing toward the preoperatively marked femoral head. For minor anatomic variation and intraoperative correction of the distal femoral or proximal tibia cuts, a $\pm 2^\circ$ block is available, or the MIS distal femoral alignment guide can be set for a 4°, 5°, or 6° valgus angle.

1. Hofmann AA, Evanich JD, Ferguson RP, Camargo MP. Ten- to 14-year clinical follow-up of the cementless Natural Knee system. *Clin Orthop*. 2001 Jul; (388): 85-94.
2. Hofmann AA, Bloebaum RD, Rubman MH, Bachus KN, Plaster R. Microscopic analysis of autograft bone applied at the interface of porous-coated devices in human cancellous bone. *Int Orthop*. 1992 Dec; 7(4): 483-93.
3. Hofmann AA, Tkach TK, Evanich CJ, Camargo MP. Posterior stabilization in total knee arthroplasty with use of an ultracongruent polyethylene insert. *J Arthroplasty*. 2000 Aug; 15(5): 576-83.
4. Bonding of porous Ti to CoCr—the Sinterlock process. Zimmer
5. Baldwin JL, El-Saied MR, Rubinstein RA, Jr. Uncemented total knee arthroplasty: report of 109 titanium knees with cancellous-structured porous coating. *Orthopedics*. 1996 Feb; 19(2): 123-30.
6. Hofmann AA, Bachus KN, Wyatt RW. Effect of the tibial cut on subsidence following total knee arthroplasty. *Clin Orthop*. 1991 Aug; (269): 63-9.
7. Smith J, Hofmann AA. Morphology of the proximal tibia in the arthritic knee. Zimmer

Increased Fixation

A well-fixed and stable implant contributes significantly to the long-term success of the total knee arthroplasty. *CSTi* porous coating provides potential for optimal ingrowth fixation.^{1,8,9,10} Each *Natural-Knee* System component is secured with smooth pegs (as opposed to porous-coated pegs) to help prevent stress shielding and to increase stabilization (except the CoCr Baseplate, which has no pegs). The femoral and tibial components feature either *CSTi* porous coating for pressfit, or gritblasting for improved bone cement/implant fixation.

Two titanium cancellous bone screws augment the component's four peripherally-placed pegs and central cruciate stem, enhancing tibial fixation of the asymmetric resurfacing and stemmed tibial components.^{7,11} The central stem improves fixation in softer bone (e.g., rheumatoid arthritic patients or osteoporotic patients). Resurfacing components provide excellent fixation in hard bone (e.g., osteoarthritic males and patients with prior high tibial osteotomies).¹²

Countersinking the 10mm metal-backed components 2-3mm improves fixation of the patella.¹³ Patellar components come in four sizes, including a 10mm thick metal-backed (*CSTi* Porous coated) and 10mm thick all-poly patella. A 7mm thick all-poly patella is available for thinner (less than 22mm) patellas, but should not be countersunk. Patellar component fixation is augmented by three peripherally-placed pegs.

Preoperative Planning

Obtain 36 in. or 52 in. standing anteroposterior and lateral radiographs of the extremity, as well as a sunrise view of the patella. The entire femur should be visualized to rule out any structural abnormality, as the distal femoral cut will be referenced from an intramedullary rod in the medullary canal.

If the intramedullary tibial instruments are used, the entire tibia should be visualized to identify any varus or valgus bowing, and the appropriate tibial entry point planned.

Templating for size is most accurate on the lateral radiograph since many patients present with a flexion contracture that distorts magnification on the anteroposterior radiograph. The intraoperative management of tibial defects is planned using bone graft, cement and/or tibial spacers.

The degree of constraint in the tibial insert may be planned, such as the use of the ultracongruent insert or traditional posterior stabilized components for more constraint in patients with posterior cruciate ligament (PCL) deficiency or in the unstable varus or valgus knee.

8. Bachus, KN. Canine and human cancellous bony ingrowth into Ti and CoCr porous-coated plugs implanted into the proximal tibia. *Ortho Trans.* 1988; 12(2): 380.
9. Leland R, Hofmann AA, Chowdhary, R. Biocompatibility and bone response of human cancellous bone to a Ti porous-coated CoCr implant. *Society of Biomaterials Meeting*; AZ; 1991.
10. Hofmann AA. Response of human cancellous bone to commercially pure Ti and CoCr alloy porous-coated cylinders. *Clinical Materials.* 1993; (14): 101-15.
11. Hofmann AA. Total knee replacement using the *Natural Knee* system. *Tech in Orthop.* 1987; 1(4): 1-17.
12. Hofmann AA. Stemmed versus resurfacing tibial components in total knee arthroplasty. *Knee Society Interim Meeting*; IL; 1991.
13. Evanich CJ, Tkach TK, von Glinski S, Camargo MP, Hofmann AA. Six- to 10-year experience using countersunk metal-backed patellas. *J Arthroplasty.* 1997 Feb; 12(2): 149-54.
14. Hofmann AA, Plaster RL, Murdock LE. Subvastus (Southern) approach for primary total knee arthroplasty. *Clin Orthop.* 1991 Aug; (269): 70-7. Review.

Patient Preparation

To prepare the limb for MIS total knee arthroplasty, adequate muscle relaxation is required. This may be accomplished with a short-acting, nondepolarizing muscle relaxant. The anesthesiologist should adjust the medication based on the patient's habitus and weight, and administer to induce a complete muscle paralysis for a minimum of 30-40 minutes. This will facilitate the eversion of the patella, if desired, and minimize tension in the remaining quadriceps below the level of the tourniquet. It is imperative that the muscle relaxant be injected prior to inflation of the tourniquet. Alternatively, spinal or epidural anesthesia should produce adequate muscle relaxation.

Apply a proximal thigh tourniquet and inflate it with the knee in hyperflexion to maximize that portion of the quadriceps that is below the level of the tourniquet. This will help minimize restriction of the quadriceps and ease patellar eversion.

Once the patient is draped and prepped on the operating table, determine the landmarks for the surgical incision with the leg in extension.

Because the knee must be repositioned multiple times and in multiple positions during surgery, the use of a leg positioner is recommended. A lateral trochanteric pad allows for excellent stability of the extremity.

Incision and Exposure

The incision may be made with the leg in extension or flexion depending on surgeon preference. The minimum length of the incision is dependent on the size of the femoral component and the ability to obtain adequate exposure in order to perform the surgery accurately and expeditiously. Although the goal of a MIS technique is to complete the surgery with an approximately 10cm-14cm incision, it may be necessary to extend the incision if visualization is inadequate or if subluxation of the patella is not possible without the risk of avulsion at the tibial tubercle. If the incision must be extended, it is advisable to extend it gradually and only to the degree necessary. The advantage of a MIS technique is dependent on maintaining the extensor mechanism insertion.

Begin making a slightly oblique parapatellar skin incision beginning at the superomedial corner of the patella, and extend it approximately 10cm-12cm to the medial center of the tibial tubercle. Be careful to avoid disruption of the tendon insertion. Divide the subcutaneous tissue to the level of the retinaculum.

The arthrotomy is the surgeon's choice. Options include a subvastus approach, mid-vastus approach, or a mini medial arthrotomy. Also, depending on surgeon preference, the patella can either be everted or subluxed. Eversion of the patella may require a longer skin incision and more detachment of the quadriceps to the patella. Rehabilitation may be facilitated by the least invasion of the quadriceps muscle.

Technique Tip: Using electrocautery to complete the exposure will help minimize bleeding after deflation of the tourniquet, as well as late muscle bleeding.

Subvastus Approach

The subvastus medial arthrotomy has been slightly modified to optimize minimally invasive surgery. It provides excellent exposure for TKA while preserving all four attachments of the quadriceps to the patella. This approach does not require patellar eversion, minimizes disruption of the suprapatellar pouch, and facilitates rapid and reliable closure of the knee joint.

Dissect the subcutaneous tissue down but not through the fascia that overlies the vastus medialis muscle.

Identify the inferior border of the vastus medialis muscle, and incise the fascia at approximately 5cm to 8cm medial to the patellar border (Fig. 1) to allow a finger to slide under the muscle belly but on top of the underlying synovial

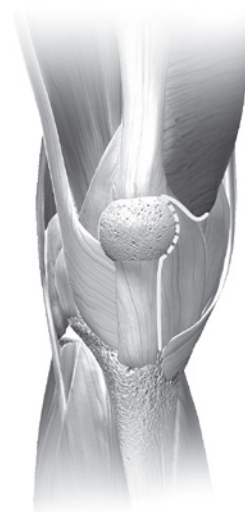


Fig. 1

lining of the knee joint. Use the finger to pull the vastus medialis obliquus muscle superiorly and maintain slight tension on the muscle.

Use a knife or electrocautery to free the vastus medialis from its confluence with the medial retinaculum, leaving a small cuff of myofascial tissue attached to the inferior border of the vastus medialis.

The tendonous portion of the vastus medialis extends distally to insert at the midpole of the medial border of the patella. Be careful to preserve that portion of the tendon to protect the vastus medialis muscle during subsequent steps. An incision along the inferior border of the vastus medialis to the superior pole of the patella will result in a tear, split, or maceration of the muscle by retractors.

Incise the underlying synovium in a slightly more proximal position than is typical with a standard subvastus approach. This will allow a two-layer closure of the joint. The deep layer will be the synovium, while the superficial layer will be the medial retinaculum and the myofascial sleeve of tissue that has been left attached to the inferior border of the vastus medialis.

Carry the synovial incision to the medial border of the patella. Then turn directly inferiorly to follow the medial border of the patellar tendon to the proximal portion of the tibia. Elevate the medial soft tissue sleeve along the proximal tibia in a standard fashion.

Place a bent-Hohmann retractor in the lateral gutter and lever it against the robust edge of the tendon that has been preserved just medial and superior to the patella. Retract the patella and extensor mechanism into the lateral gutter. If necessary,

mobilize the vastus medialis either from its underlying attachment to the synovium and adductor canal, or at its superior surface when there are firm attachments of the overlying fascia to the subcutaneous tissues and skin. The fat pad should be preserved if possible.

Flex the knee to 70°. The patella will stay retracted in the lateral gutter behind the bent-Hohmann retractor, and the quadriceps tendon and vastus medialis will lie over the distal anterior portion of the femur. To improve visualization of the distal anterior portion of the femur, place a thin knee retractor along the anterior femur and gently lift the extensor mechanism during critical steps of the procedure. Alternatively, bring the knee into varying degrees of extension to improve visualization by decreasing the tension on the extensor mechanism.

Remove the anterior horns of the medial and lateral meniscus. Perform a preliminary proximal release of the tibial soft tissue and extend it to the posteromedial corner of the tibia. Remove any osteophytes to identify true bony landmarks and dimension. If a marked deformity is present, perform further soft tissue release prior to making the bone cuts, however, this can usually be best titrated once the trials are in place.

Mid-vastus Approach

Make a medial parapatellar incision into the capsule, preserving approximately 1cm of peritenon and capsule medial to the patellar tendon. This is important to facilitate complete capsular closure.

Split the superficial enveloping fascia of the quadriceps muscle percutaneously in a proximal direction over a length of approximately 6cm. This will mobilize the quadriceps and allow for significantly greater lateral translation of the muscle while minimizing tension on the patellar tendon insertion.

Split the vastus medialis obliquus approximately 1.5cm-2cm (Fig. 2).

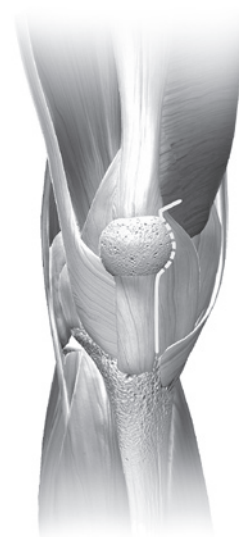


Fig. 2

Use blunt dissection to undermine the skin incision approximately 1cm-2cm around the patella. Slightly flex the knee and remove the deep third of the fat pad.

The patella can either be everted or subluxed. If everting the patella, release the lateral patellofemoral ligament to facilitate full eversion and lateral translation of the patella. Then use hand-held three-pronged or two-pronged hooks to begin to gently evert the patella. Be careful to avoid disrupting the extensor insertion. To help evert the patella, slowly flex the joint and externally rotate the tibia while applying gentle pressure. Once the patella is everted, use a standard-size Hohmann retractor or two small Hohmann retractors along the lateral flare of the tibial metaphysis to maintain the eversion of the patella and the extensor mechanism.

Note: It is imperative to maintain close observation of the patellar tendon throughout the procedure to ensure that tension on the tendon is minimized, especially during eversion of the patella and positioning of the patient. Also be careful not to allow the split in the vastus medialis obliquus to extend more than 4.5cm proximal during retraction to gain exposure or neurovascular compromise to the most medial aspect of the quadriceps can occur.¹⁵

Remove any large patellar osteophytes.

Release the anterior cruciate ligament, if present. Perform a subperiosteal dissection along the proximal medial and lateral tibia to the level of the tibial tendon insertion. Then perform a limited release of the lateral capsule (less than 5mm) to help minimize tension on the extensor mechanism.

Mini Medial Arthrotomy

Minimally invasive total knee arthroplasty can be performed with a limited medial parapatellar arthrotomy. Begin by making a 10cm-14cm midline skin incision from the superior aspect of the tibial tubercle to the superior border of the patella (Fig.3). Following subcutaneous dissection, develop medial and lateral flaps, and dissect proximally and distally to expose the extensor mechanism. This permits mobilization of the skin and subcutaneous tissue as needed during the procedure. In addition, with the knee in flexion, the incision will stretch 2cm-4cm due to the elasticity of the skin, allowing broader exposure.

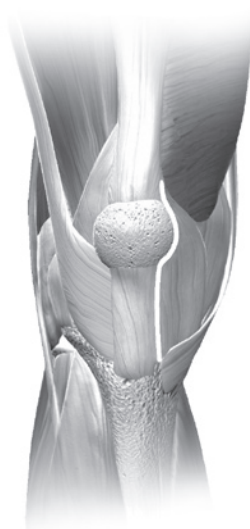


Fig. 3

The goal of minimally invasive surgery is to limit the surgical dissection without compromising the procedure. The medial parapatellar arthrotomy is used to expose the joint, but the proximal division of the quadriceps tendon should be limited to a length that permits only lateral subluxation of the patella without eversion. Incise the quadriceps tendon for a length of 2cm-4cm initially. If there is difficulty

displacing the patella laterally or if the patellar tendon is at risk of tearing, extend the arthrotomy proximally along the quadriceps tendon until adequate exposure is achieved.

Sublux the patella laterally and carefully place retractors to protect the supporting soft tissue structures. The incision can be moved as a “mobile window” from medial to lateral and from superior to inferior as necessary to aide in visualization without applying undue force to the skin and subcutaneous tissues.

15. Cooper RE, Trinidad G, Buck, WR. Midvastus Approach in Total Knee Arthroplasty. J Arthroplasty 1999; 14(4): 505-508.

Surgical Technique Summary

Bone Cuts

Bone resorption and connective tissue formation occur when bone is surgically traumatized and heated to above 45° centigrade for longer than one minute. To control thermal injury, cool the saw blade using constant irrigation when making bone cuts.¹⁶ All femoral bone cuts are made with the posterior and anterior cut blocks (Figs. 4a and 4b). Posterior cuts are made first to create additional joint space and are required to facilitate placement of the anterior cut block.



Fig. 4a



Fig. 4b

To ensure that a perfectly flat surface has been created, use a saw guide or an auxiliary cutting block to sight all bone cuts in two planes (Fig. 5).



Fig. 5

Each cutting block can be stabilized first by drilling with a 5 in. x 1/8 in. (3.2mm) drill bit that remains loaded in the Jacob's chuck. The drilled holes are then filled with 3 in. x 1/8 in. smooth pins. This is especially important in softer bone. The first calibrated mark on the drill point indicates the drilling depth of the tibial baseplate pegs; the second mark is for the metal-backed patella pegs (Fig. 6).

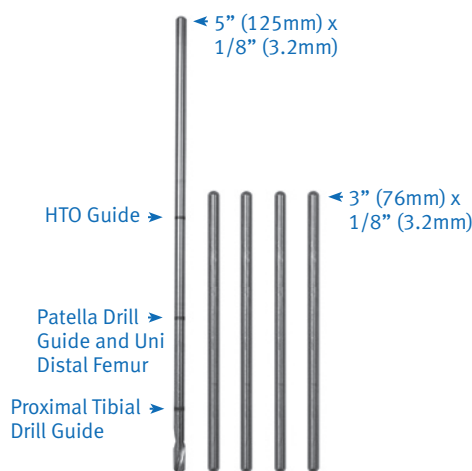
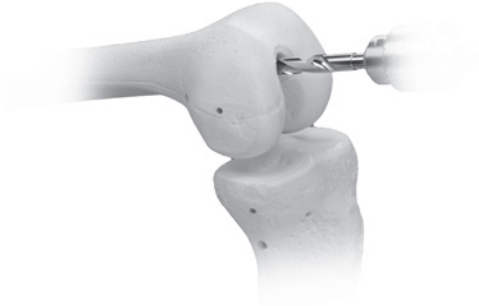

Fig. 6

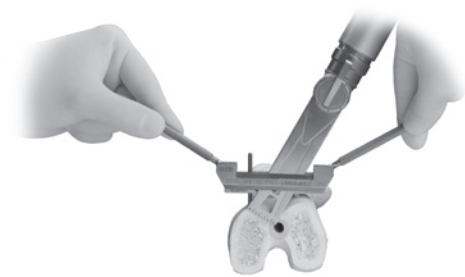1/2 in. wide and 1 in. wide (.050 in. thick, .040 in. blade used for patella osteotomy) saw blades should be used for accurate and consistent results. The sharpness of a new blade decreases both operating time and injury to the bone.

16. Krause WR, Bradbury DW, Kelly JE, Lunceford EM. Temperature elevations in orthopaedic cutting operations. J Biomech. 1982; 15(4): 267-75.


Preparing the Femur



Step 1. Locate the intramedullary canal



Step 2. Cut the distal femur



Step 3. Drill distal femoral holes and calibrate the femur

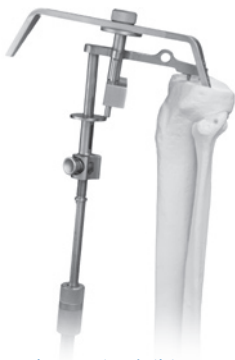

Step 4. Cut the posterior femur and posterior chamfer



Step 5. Cut the anterior femur and anterior chamfer

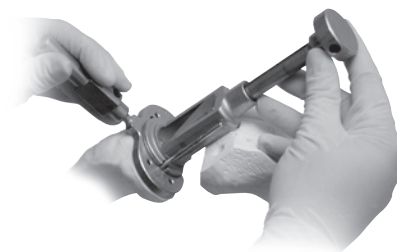Preparing the Tibia



Step 1. Cut the proximal tibia



Step 2. Size and drill the proximal tibia

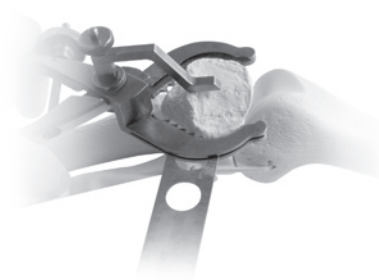

Step 3. Broach the tibia (for stemmed components only)

Preparing the Patella




Step 1. Determine the patellar thickness



Step 2. Osteotomize the patella



Step 3. Plane the patella



Step 4. Drill holes for the pegs

Surgical Approach

Locating the Medullary Canal

Make a 5/16 in. (8mm) hole in line with the femoral shaft (Fig. 7a).

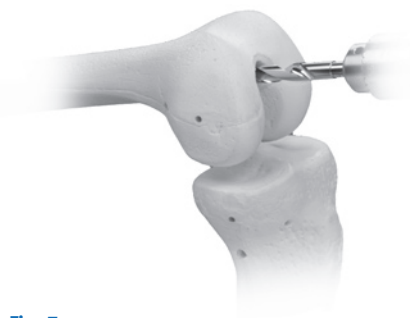

Fig. 7a

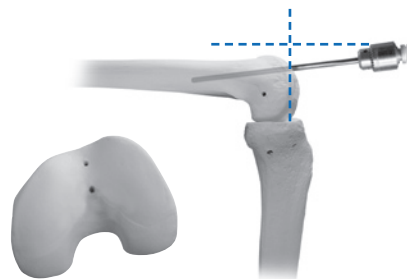
Center the starting point distally on the trochlear groove 1-2mm anterior to the true roof of the intercondylar notch (Fig. 7b).



Correct

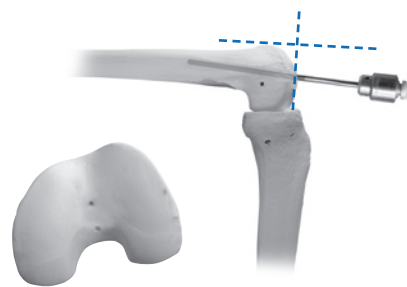
Fig. 7b

The placement of the hole determines the flexion/extension position of the femoral component on the femur. The drill hole must be aligned with the femoral shaft in both the frontal and lateral planes. Incorrect anterior drill hole placement leads to extension of the femoral component with potential notching of the anterior cortex. Incorrect posterior drill hole placement leads to flexion of the femoral component (Figs. 7c and 7d).



Incorrect

Fig. 7c



Incorrect

Fig. 7d

NOTE: Slightly toggle the drill upon exiting to center the intramedullary rod and vent the medullary canal in order to prevent pressurization.

Slowly and fully insert the fluted 5/16 in. intramedullary rod into the isthmus (Fig. 8). If the rod does not slide easily into the canal, reassess the orientation of the hole to ensure that it is in line with the femoral shaft. Aim slightly lateral to avoid running into the medial cortex.



Fig. 8

Cutting the Distal Femur

Set the angle for the valgus cut on the Distal Femoral Alignment Guide for 4, 5, or 6 degrees. The holes are marked at either the top or bottom of the holes on the alignment guide with an 'L' or an 'R' and a 4, 5, or 6, designating left or right and the degree of the valgus cut.

Dial the medial or lateral adjustable screw down to the defective distal femoral condyle (Fig. 10). If both condyles are defective (e.g., a patient with rheumatoid arthritis), slightly dial down both adjustable screws to compensate for the lost cartilage.

Before stabilizing the MIS Distal Femoral Alignment Guide, line up the posterior portion of the guide with a line that runs parallel to the posterior femoral condyles in order to achieve the correct rotational alignment of the guide (Fig. 11). Drill and fill the lateral cannulated adjustable screw with a 5 in. x 1/8 in. smooth pin to prevent rotation.

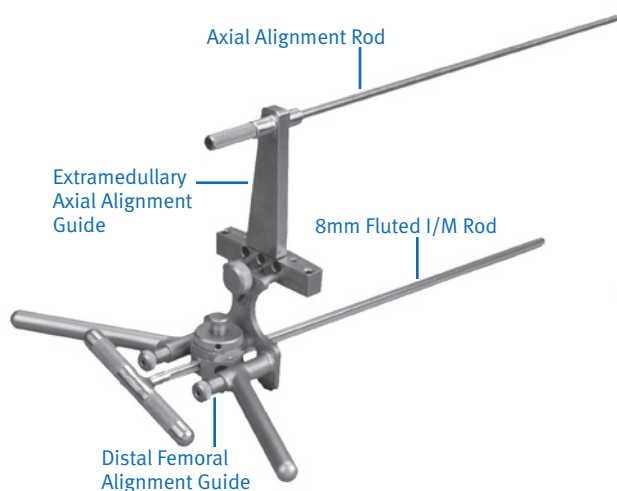


Fig. 9

Fig. 10




Fig. 11

The guide facilitates a cut that is 4-6° valgus from the anatomic axis. This position orients the first cut perpendicular to the mechanical axis. Check the position by attaching the External Alignment Tower, which should be in direct alignment with the femoral head (Fig. 12). Make further minor varus-valgus adjustments by adjusting the threaded screws. Stabilize the cutting block by drilling through the condyles completely and filling the holes with two 3 in. x 1/8 in. smooth pins. Release the thumb-screw from the cutting block, and remove the distal femoral alignment assembly, leaving the cutting block in place.



Fig. 12

Tap the smooth pins flush with the cutting block to eliminate saw impingement and to allow easy removal and replacement of the cutting block. Cut the distal femoral condyles using a new 1 in. saw blade (Fig. 13).

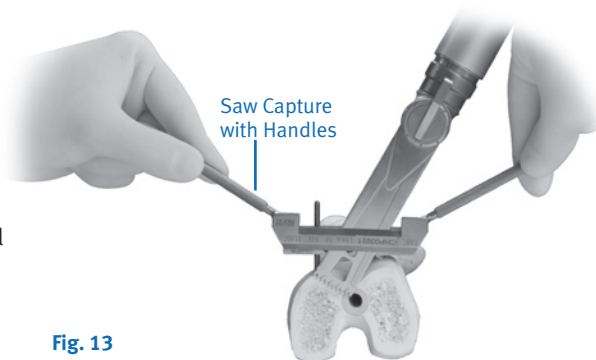


Fig. 13

The $\pm 2^\circ$ cutting block can be used to cut the femur from 2-8° of valgus, but it is rarely needed. If using the block, place it over the pins at the 11mm holes. Because all other femoral cuts are based on the distal cut, it must be perfectly flat before the surgery is continued. Use an Auxiliary Cutting Block to check for flatness (Fig. 14).

A central high spot near the intercondylar notch may persist and will require additional planing. The high spot must be eliminated to keep the femoral component from becoming “high centered” when it is implanted. Eliminate the high spot by making a few extra passes with the saw blade using a slight upward spring of the blade against the bone.

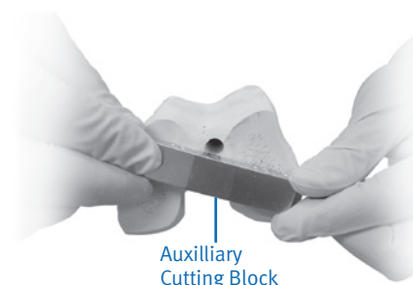



Fig. 14

Drilling the Distal Femoral Holes and Calibrating the Femur

With the knee maximally flexed, center the MIS Distal Femoral Sizing/Drill Guide on the femoral condyles. Position the guide by referencing the posterior femoral condyles on the skids, and use the captured set pins to stabilize it (Fig. 15).

Distal Femoral Drill Guide with Sizing Caliper



If a defective posterior condyle is present, pin the good condyle with the jig, and rotate the opposite posterior skid away from the posterior defect 1mm to 2mm. The drill holes may be set for 3° of external rotation (left or right). To externally rotate the femoral component set the rotation before placing the guide onto the distal femur.

The Distal Femoral Drill Guide also acts as a caliper to determine the correct anterior/posterior femoral size (Fig. 16).




Fig. 16

If the mark falls between sizes, there are three things that can be done to accommodate this situation. First, the MIS 2mm Shift Guide can be placed on the distal femur, referencing the set pin holes from the Distal Sizing/Drill Guide (Fig. 17). As implied, this will shift the reference drill holes for the MIS Femoral Cut Blocks 2mm anteriorly, thus allowing use of the smaller size femoral component. Second, the MIS 3° Flexion Block can be used to cut the distal femur in 3° of additional flexion, reducing the risk of femoral notching and allowing the use of the smaller sized femoral component. Third, the larger size is chosen to avoid notching the anterior cortex. When the femoral size is determined the two reference holes are made with the 1/4in Stop Drill through the 2mm Shift Guide or the Distal Femoral Drill Guide (Fig. 18).



Fig. 17




Fig. 18

Finishing the Femur (Option 1)

Place the appropriately-sized MIS Femoral Finishing Guide into the drilled reference holes as established by the Distal Femoral Sizing/Drill Guide. Additional guide stability is attained by drilling and pinning the 1/8 in. oblique medial and/or lateral holes in the Femoral Finishing Guide (Fig. 19).



Fig. 19

A resection guide (angel wing) can be used to assure the desired resection level will be achieved on the anterior cortex (Fig. 20). The cut slots accommodate a saw blade thickness of .050 in. or 1.27mm. The posterior and posterior chamfer cuts can be made with a 1 in. wide blade with the knee flexed at 110°. The anterior and anterior chamfer cuts can then be made with a 1/2 in. wide blade with the knee flexed at 60° (Fig. 21).




Fig. 20



Fig. 21




Fig. 22

The trochlear recess notch is then created. This can be facilitated by using a 1/2 in. reciprocating saw to make the bottom of the U-shaped notch cut. The notch cut is finished by passing the notch chisel through the trochlear recess with a mallet (Fig. 22). Alternatively, the Notch Chisel can be inserted into the trochlear recess in the cutting guide in an inverted fashion to make the side cuts of the trochlear recess, followed by passing the notch chisel through the cutting guide to finish the bottom of the U-shaped notch cut.

When all femoral cuts are completed, the finishing guide is removed from the distal femur by first removing the 1/8 in. pins, and inserting the MIS Threaded Handle into the Femoral Finishing Guide (Fig. 23). The Slaphammer Extractor is inserted into the hole in the extraction handle to facilitate removal of the Femoral Finishing Guide (Fig. 24).

Fig. 23

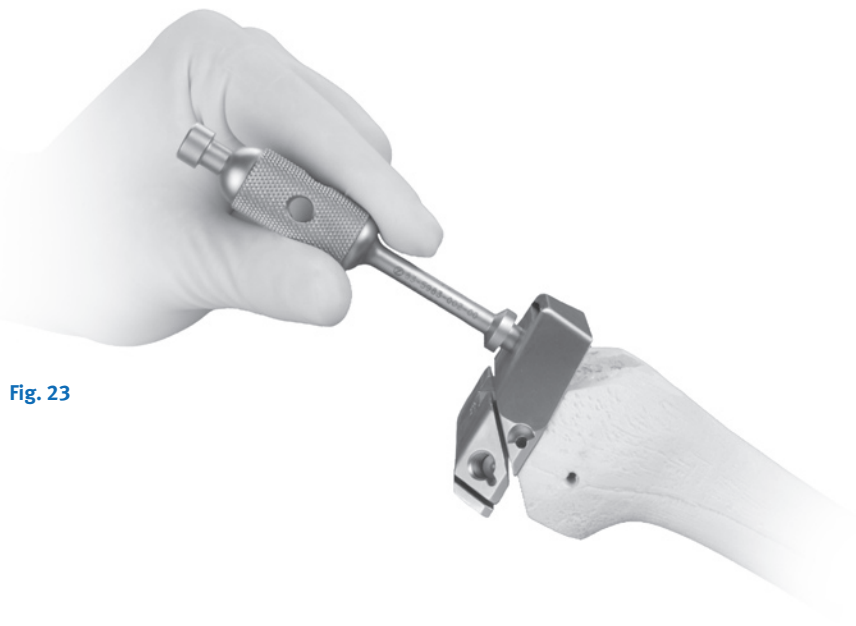
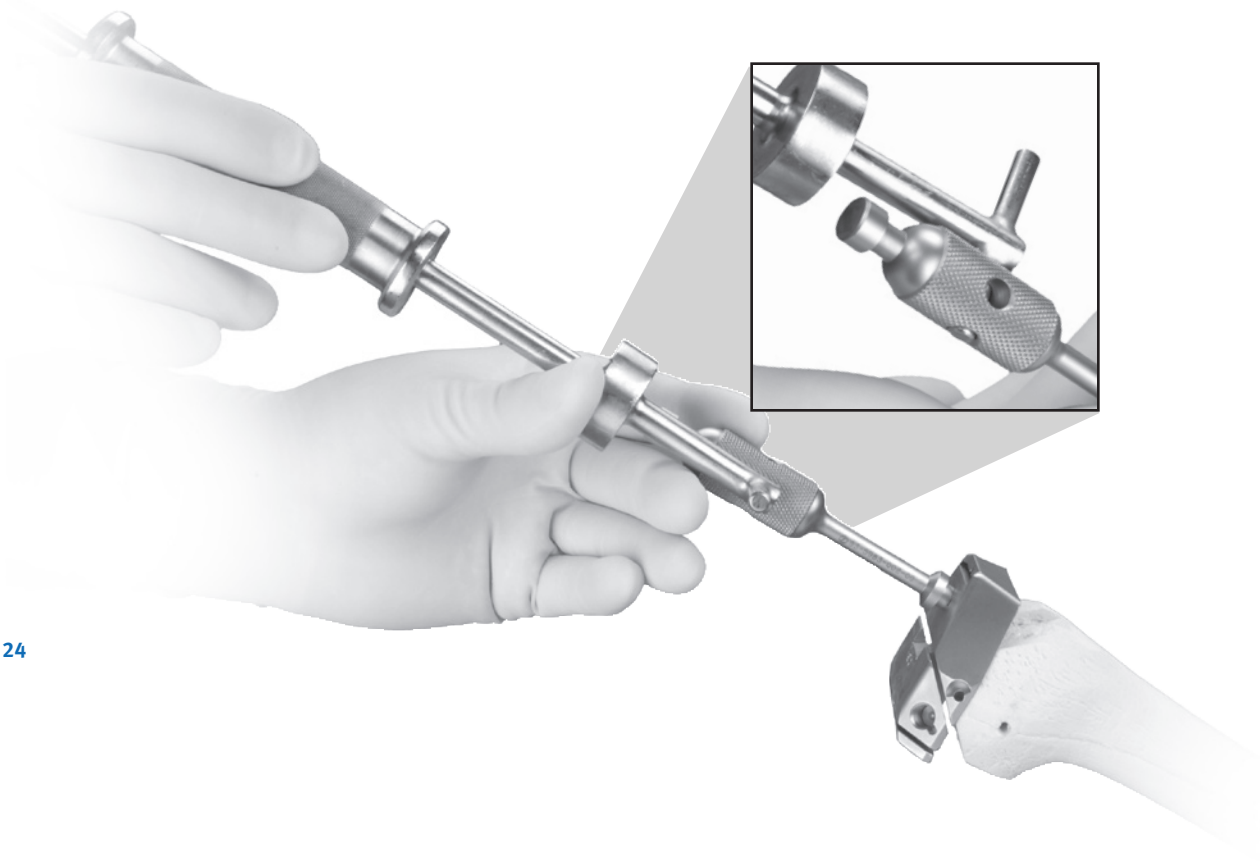


Fig. 24



Finishing the Femur (Option 2)

Making the Posterior/Posterior Chamfer Cuts

This step is facilitated by placing the knee in about 110 degrees of flexion. Place the appropriate-sized MIS Posterior Cutting Block into the reference holes. Additional block stability can be achieved by drilling and pinning the block in place. Make the posterior cut and then the posterior chamfer cut (Fig. 25). In smaller knees, use of a narrower saw blade is recommended. After removing the stabilizing pins, the slaphammer can be used to remove the MIS Posterior Cutting Block.




Fig. 25

Making the Anterior/Anterior Chamfer Cuts and the Trochlear Recess Cut

Place the appropriate-sized MIS Anterior Cutting Block into the reference holes. Additional block stability can be achieved by drilling and pinning the block in place. After securing the block, placing the knee at 60 degrees of flexion improves visualization of the saw blade exiting the anterior cortex. Make the anterior cut and then the anterior chamfer cut (Fig. 26).

Make the bottom of the U-shaped notch cut using a 1/2 in. saw blade, and complete the notch cut using the notch chisel and a mallet (Fig. 27a and 27b). After removing the stabilizing pins, the slaphammer can be used to remove the MIS Anterior Cutting Block.




Fig. 26




Fig. 27a




Fig. 27b

Preparing the Proximal Tibia

Maximally flex the knee and excise the anterior cruciate ligament along with any remaining meniscus. Recess the PCL about 8-9mm using a small knife blade. Place the large bent-knee retractor behind the tibia just lateral to the PCL to sublunate the posterior margin of the tibia anterior to the femur. Place a smaller bent-knee retractor medially. Place two retractors laterally with one anterolaterally to retract the patellar tendon and fat pad.

Using the Extramedullary Tibial Technique

After adjusting the Proximal Tibial Cutting Guide to the approximate tibial length, place the jig on the tibia and stabilize it by tapping the longest pin into the central tibial plateau on the proximal portion of the guide, just anterior to the tibial spine in the midline (Fig. 28).



Fig. 28

Setting the Rotation

First, obtain proper rotational alignment by using the tibial tubercle as a guide. Place a 5 in. pin through the slot in the proximal portion of the guide (Fig. 29) and/or aligning the distal pin of the cutting block just medial to the tibial tuberosity.

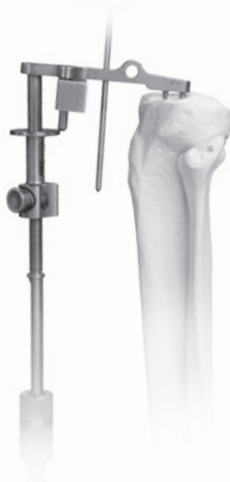

Fig. 29

The posterior edges of the proximal tibial plateau should be aligned parallel with the cutting block (Fig. 30). Lock the jig into position by tapping the shorter pin into the proximal tibia.




Fig. 30

Setting the Varus/Valgus Angle of the Tibial Cut

In order to achieve a perpendicular cut in the medial/lateral plane, maintain the medial/lateral position of the distal portion of the MIS Extramedullary Guide so that it is in the middle of the ankle (Fig. 31a). If the patient has an excessive proximal tibial varus deformity, the varus/valgus angle on the cut block can be adjusted by sliding the distal portion of the MIS Extramedullary Ankle Alignment Guide laterally to create a slightly varus cut, up to approximately 2° to allow for resection of a more symmetrical wedge of proximal tibia. The alignment guide should still fall within the confines of the ankle joint, although it will be slightly (2°) lateralized at the distal tibiofemoral joint (Fig. 31b), creating an overall end alignment of 4° valgus instead of 6° valgus.



Fig. 31a



Fig. 31b

Setting the Posterior Slope

Re-establish the patient's posterior slope by inserting a 5 in. x 1/8 in. smooth pin through the 16mm hole of the cutting block and over the least involved portion of the tibial plateau.

Reproduce the posterior slope of the proximal tibia by moving the distal portion of the jig anteriorly or posteriorly until the pin is parallel to the proximal tibia (Fig. 32). The posterior tilt of the tibia may range from 4-12°. The goal is to cut parallel to the joint surfaces. Avoid excessive posterior slope especially if the PCL is to be substituted.

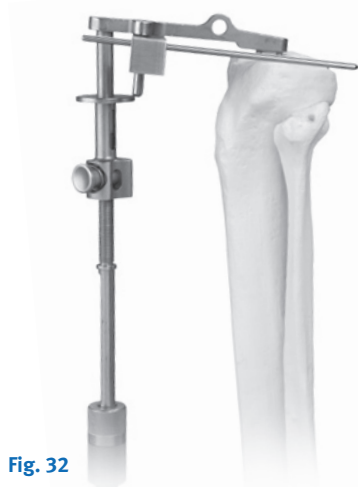

Fig. 32

Level of Resection

Finally, establish the level of the tibial cut by placing the stylus end marked "PRIMARY" over the least-involved weight-bearing portion of the tibial plateau in order to re-create the joint line. The stylus position references a 7mm bone cut—the minimum amount of bone that should be resected to accommodate the thinnest tibial component (9mm when the PCL is sacrificed). With a varus deformity, the reference point is typically the highest peripheral portion of the lateral plateau. With a valgus deformity, the

reference point is typically the highest portion of the medial tibial plateau.

Cutting the Tibia

Dial down the cutting block until the tip of the stylus has reached good cartilage (Fig. 33).

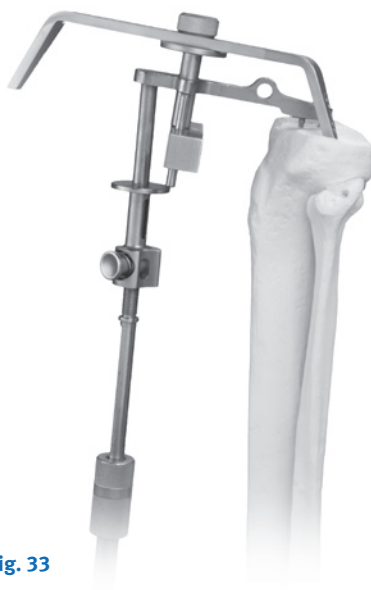

Fig. 33

Stabilize the cutting block by drilling through the 7mm holes and filling them with two 3 in. x 1/8 in. smooth pins. To avoid the drill point skiving off the medial cortex, mark the drilling location through the appropriate drill hole in the tibia saw guide.

Next, take the drill bit outside the saw guide and drill through the cortex at the previously marked spot. Place the drill bit back through the appropriate drill hole and drill through the tibia. Once the cutting block has been stabilized, remove the stylus and the remainder of the proximal tibial cutting guide using the slaphammer. Tap the 3 in. x 1/8 in. smooth pins so that they are flush with the cutting block.

In order to verify the varus/valgus angle of the desired tibial cut, place the tibial alignment checker on the cutting block. If the tip of the rod falls in the middle of the ankle (Fig. 34a), then a perpendicular tibial cut will be achieved. If the tip of the rod points to the lateral malleolus, a 2° varus tibial cut will be achieved (Fig. 34b), creating an overall end alignment of 4° valgus instead of 6° valgus.

a. Perpendicular Cut b. 2° Varus Cut



Fig. 34

Most patients require a minimum of 7mm of resection to allow use of at least a 9mm tibial component. Move the cutting block down in 2mm increments to eliminate bone defects and match the thicknesses of the available tibial inserts. Use the small, angled knee retractors to protect the medial and lateral collateral ligaments. If preserving the PCL, the PCL should be well protected with the large angled knee retractor and a 1/4 in. osteotome. Protect the PCL by placing a small (1/4 in. or 1/2 in.) osteotome just anterior and deep to the ligament, in order to prevent the saw blade from going too posterior.

Using a 1 in. saw blade, cut the proximal tibia (Fig. 35).




Fig. 35

Measure the resected tibia in areas of relatively normal cartilage using the caliper (Fig. 36).



Fig. 36

Add 1mm to this measurement for bone loss from the saw blade to predict the thickness of the tibial replacement in a PCL sparing procedure, or 2mm if the PCL is sacrificed.

Check the tibial cut for flatness by sighting along the block or by using an auxiliary cutting block as a level (Fig. 37).



Fig. 37

Sizing and Drilling the Proximal Tibia

Cruciate-Stemmed Baseplates

Position the Proximal Tibial Drill Guides on the cut surface of the proximal tibia and select the largest-sized tibial baseplate that does not overhang. Medial overhang is a recognized source of pes bursitis and should be avoided. To prevent medial overhang, drill the central hole on the medial side to the first mark on the calibrated drill bit and fill it with a 3 in. x 1/8 in. smooth pin. Adjust the final rotation based on the tibial tubercle, and drill and fill the lateral central hole (Fig. 38).

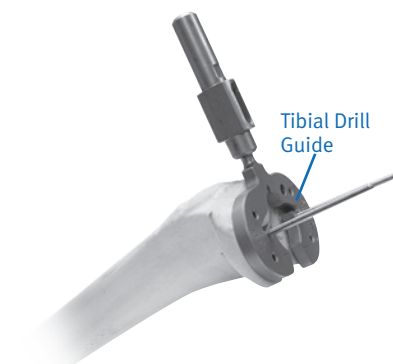


Fig. 38

Check the alignment of the tibial cut by using the Proximal Tibial Drill Guide in conjunction with an alignment rod. Drill the remaining four peripheral holes to the same depth. Stabilize the drill guide by inserting smooth pins through the drilled holes. If a drill hole or one of the four baseplate pegs falls on sclerotic bone, enlarge the hole slightly by toggling the drill bit, as the implant requires that a 4.8mm peg fits into a 3.2mm hole. Insert and impact the small (for baseplate sizes 0 and 00), medium (for baseplate sizes 1 and 2), or large (for baseplate sizes 3-5) tibial broach if a metal-backed stemmed tibial component is to be used.

Modular Cemented Tibial Baseplate

Position the Modular Tibial Drill Guides on the cut surface of the proximal tibia and select the tibial baseplate that provides the most coverage without overhanging. Medial overhang is a recognized source of pes bursitis and should be avoided. To prevent medial overhang, drill the central hole on the medial side to the first mark on the calibrated drill bit and fill with a 3 in. x 1/8 in. smooth pin. Adjust the final rotation based on the tibial tubercle, and drill and fill the lateral central hole. Drill the remaining four peripheral holes to the same depth (Fig. 39).

Drill and fill the
medial side first

Fig. 39

Check the alignment of the tibial cut using the Modular Tibial Drill Guide in conjunction with an alignment rod. Position the appropriately-sized Modular Tibia Boss Reamer Guide on the Modular Tibia Drill Guide (Fig. 40) and assemble the Modular Tibia Boss Reamer Stop to the Modular Tibia Boss Reamer (Fig. 41).



Fig. 40

Depress button on Reamer Stop and slide to the appropriate position on the Reamer.



Fig. 41

The Modular Tibia Boss Reamer Stop can be positioned on the Tibial Boss Reamer in two positions to prepare for: 1) the baseplate boss only, and; 2) the baseplate with a 14.5 x 75mm stem extension (Fig. 42).



Fig. 42

After positioning the Reamer Stop at the proper position, ream through the Reamer Guide until the reamer stop contacts the reamer guide shoulder (Fig. 43).

Note: The Reamer Stop should not be assembled from the reamer end in order to avoid dulling the reamer cutting teeth.




Fig. 43

Position the appropriately-sized Modular Tibia Keel Broach on the Modular Tibia Drill Guide and impact (Fig. 44).




Fig. 44

If desired, achieve 2mm of press by impacting the broach to the groove just below the impaction head (Fig. 45).




Fig. 45

Note: If selecting the 14.5 x 75mm stem extension, remove the tip of the Modular Tibia Keel Broach and assemble the stem trial to the keel broach prior to impaction (Fig. 46).




Fig. 46

Preparing the Patella

It may be difficult to prepare the patella with the trial femoral and tibial components in place. The joint will be decompressed after femoral and tibial bone resections and without trials in place to allow eversion of the patellar to at least a 90 degree angle. Place the leg in full extension and stabilize the patella with one or two inverted towel clips or Weber clamps to keep the patella partially everted. Incise soft tissue around the patella down to the insertion of the quadriceps and patellar tendons using an electrocautery knife. Before making any bone cuts, determine the maximum thickness of the patella using a caliper (Fig. 47).



Fig. 47

Using a 1/8 in. drill, drill the highest portion of the medial facet perpendicular to the articular surface approximately 12mm deep (Fig. 48).

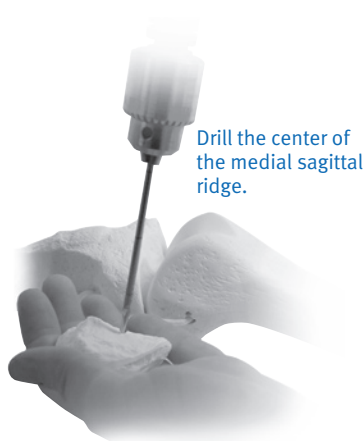

Fig. 48

This acts as a guide for proper medialization of the patella.¹⁷ Next, use the Patella Osteotomy Guide with the stylus set for the desired amount of resection (usually 7mm). If the patella is very worn, resect less bone. At least 10mm of bony patella should be retained.

Apply the guide medially and laterally with the jaws at the osteochondral juncture and the handles of the jig oriented toward the foot. The jaws should be parallel to the dorsal surface of the patella. Position the stylus over the most prominent point on the patella. If the 10mm component is countersunk, position the stylus for 7mm of resection. Make the cut with a 1 in. saw blade (Fig. 49).

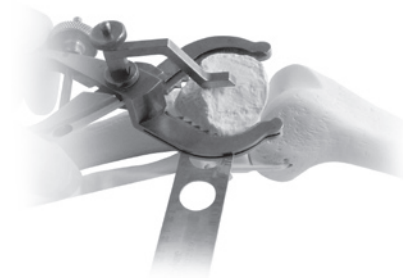

Fig. 49

17. Hofmann AA, Tkach TK, Evanich CJ, Camargo MP, Zhang Y. Patellar component medialization in total knee arthroplasty. J Arthroplasty. 1997 Feb; 12(2): 155-60.

Using the sizing template (Fig. 50), select the maximum-sized patella that does not overhang (sizes 0 to 3). Eccentric placement of the patella 3-4mm toward the medial facet allows for better tracking. Use the 1/8 in. drill hole as a reference for proper medialization.

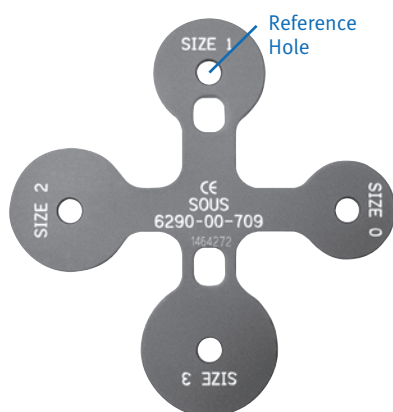


Fig. 50

Place the patellar clamp with the appropriately-sized patella bushing over the cut surface of the patella and center it slightly toward the medial facet and over the 1/8 in. drill hole (Fig. 51).



Fig. 51

Prepare the surface by applying gentle pressure with the matching size cutter (Fig. 52) for 5-10 seconds at a time until the desired thickness is achieved.



Fig. 52

Place the caliper through the inferior hole of the patella clamp and over the patella bushing (Fig. 53).



Fig. 53

If the 10mm metal-backed component is selected, it should be recessed 2-3mm. It is contraindicated to countersink the 7mm all-poly patella.

Example: If the patellar thickness is 25mm, the thickness will be 18mm after resection. The final thickness of the countersunk area should be 15mm for use with a 10mm-thick patella component.

With the clamp still in place, insert the drill guide into the patella bushing. If a metal-backed patella is selected, drill the three smaller holes for the patella pegs with a 5 in. x 1/8 in. drill bit and successively fill them with 3 in. x 1/8 in. smooth pins (Fig. 54).

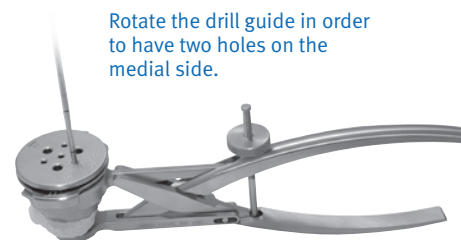


Fig. 54

Each hole must be drilled and filled before proceeding to the next hole to ensure an equal distance between holes. If the all-poly patellar component is selected, use the all-poly patella stop drill to drill the three larger holes. The peg holes are in the same location on all of the patellar sizes.

Separate patella trials are available for 7mm and 10mm all-poly patellae, as well as 10mm metal-backed patellae.

Trial Reduction

Prior to trial reduction, remove any posterior osteophytes on the femur using a 3/4 in. curved osteotome while lifting the femur with a bone hook. Osteophyte removal is required for maximum knee flexion.

Apply the tibial baseplate and insert trials first, based on the measured tibial thickness. Insert the appropriate femoral trial (Fig. 55).

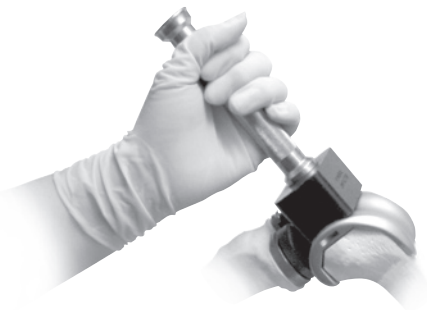

Fig. 55

Any fine-tuning of soft tissue releases should be done at this time (see Soft Tissue Balancing section). Check stability in full extension, 20° of flexion, and full flexion. If the PCL is intact, slight medial and lateral laxity should be allowed. Full extension must be obtained on the operating table. If the PCL is absent, select one size thicker for the tibial insert. The slight flexion deformity this creates will stretch out over the first 6 months. It is suggested that the PCL be resected intentionally if the patient has more than 10° varus or valgus deformity or more than a 10-15° flexion contracture preoperatively.

Use an ultracongruent insert or standard posterior stabilized components for a PCL deficient knee.

Note: See Soft Tissue Balancing section on page 29.

With the leg in full extension, hold the alignment rod (two pieces assembled together) between the center of the ankle and approximately 2cm medial to the anterior superior iliac spine (Fig. 56).

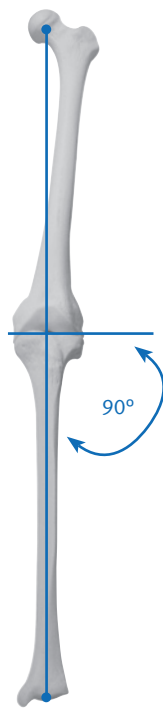


Fig. 56

This positioning allows the alignment bar to fall at the center of the knee. Remove the trial components. Remove the femoral trial component by inserting the slaphammer extractor tool between the condyles (Fig. 57).



Fig. 57

Implanting the Components

Pressfit Tibial Baseplate

Press the tibial baseplate onto the proximal tibia using the Tibial Baseplate Impactor (Fig. 58) after a bone paste slurry has been applied to the tibial surface.¹



Fig. 58

The tibial baseplate is further stabilized with 50mm x 6.5mm titanium cancellous bone screws (Fig. 59). Use the screws with slight central angulation medially and 10° central angulation laterally. Keep the screws inside the cortex to avoid soft tissue impingement.



Fig. 59

Modular Cemented Tibial Baseplate

Apply a 3-4mm layer of bone cement to the underside of the tibial component. Impact the tibial component onto the tibial surface, pressurizing the cement into the bone.



Fig. 60

If the 14.5 x 75mm stem extension is to be used, remove the baseplate's distal plug by unscrewing the "captured" stem / plug screw from the central portion of the superior side of the baseplate with the hex-head screwdriver (Fig. 60). The Stem Extension is then impacted onto the tibial baseplate using the stem impactor and the baseplate "captured" screw is tightened using the hex-head screwdriver.

Tibial Insert

Position the polyethylene insert of the chosen thickness by pushing the insert posteriorly by hand to engage the posterior tabs (Fig. 61).

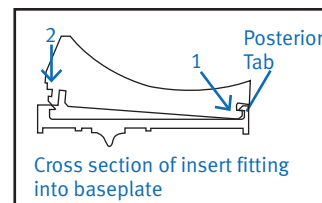
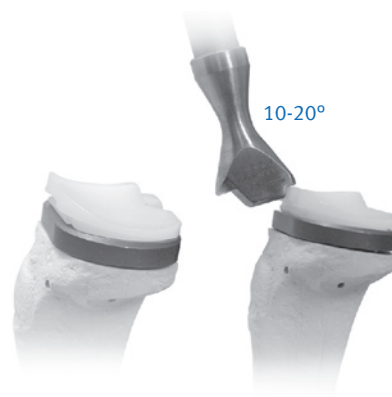


Fig. 61

Position the face of the impactor head so that the CONG, ULTRA, or PS marking faces the marking on the impaction surface of the insert to be impacted. Orient the tibial insert impactor on the anterior proximal face of the tibial insert at a 10-20° angle and impact. Soft tissue must be cleared away to allow for easy insertion.

Femoral Component

Implant the femoral component using the femoral impactor (Fig. 62). Check the range of motion and ligament stability again.



Fig. 62

Patella

Implant the patella initially by using the patella clamp in combination with the patellar inserter (Fig. 63). Ensure final component seating by lightly tapping the mallet on the inserter.




Fig. 63

Final Steps

Take the knee through the range of motion to observe patella tracking, after letting the tourniquet down. Perform a lateral release if the patella tracks laterally. With the outside-in technique, flex the knee to titrate any necessary release. Make an attempt to save the lateral superior geniculate artery and to keep the synovium intact. Release the tourniquet prior to closure. Insert a large (1/4 in.) drain for 48 hours.

Postoperative Care

Apply a long-leg surgical support stocking over a sterile occlusive dressing. Start continuous passive motion (CPM) at 0-40 degrees, and advance a minimum of 10 degrees every eight hours. Allow hospital discharge when the patient is independent in transfers and ambulation. Most patients are discharged on a home exercise program. Protected weight bearing is recommended for approximately six weeks or until good quadriceps control is present. The patients with a subvastus muscle sparing approach can usually advance to a cane by three

weeks. A cane is then used until the patient can walk without a limp. Most patients are walking without assistant devices between six and twelve weeks after surgery.

Posterior Stabilization Option

Prepare the distal femur and proximal tibia using the same technique as the *Natural-Knee* Primary cruciate-retaining femur.

After preparing the tibial and femoral surfaces, choose the appropriately-sized primary posterior stabilized (PS) femoral trial and impact it onto the distal femur using the femoral impactor.

Ensure the femoral trial is securely seated and flush on the femur, and place the PSRouter Guide onto the femoral trial so that the stabilizing pegs slide into the grooves on the femoral trial (Fig. 64).



Fig. 64

Attach the PS Router Bit with a Zimmer® fitting onto a power drill. Next, place the bit into the guide until it makes contact with the distal bony surface of the intercondylar notch. Apply downward pressure on the femoral trial with the router guide, and ream straight down with the router bit until the automatic stop is engaged (Fig. 65).




Fig. 65

While continuing to apply downward pressure, begin moving the PS guide/bit assembly posteriorly until the router guide stops (Fig. 66). Repeat this action in the anterior direction. Repeat this anterior/posterior sweeping motion until all of the intercondylar bone has been removed (one or two times is usually sufficient to remove all of the bone).

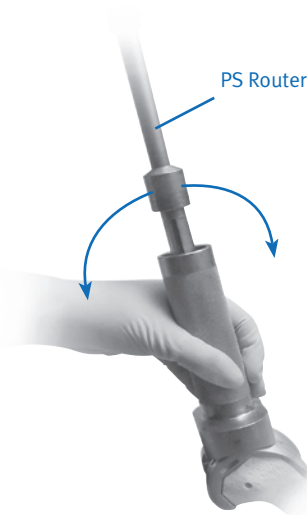


Fig. 66

Implant the trial tibial baseplate and the PS Insert Trial. Remove the trials and implant the PS Femoral Component, tibial baseplate, and tibial insert. Check range of motion and stability.

Intramedullary Tibial Option

Finding the Reference Hole

Drill a 1/4 in. hole in the proximal tibia centering from medial to lateral on the tibial plateau. Anterior/posterior positioning should fall between the middle and anterior one-third of the tibial plateau (Fig. 67).

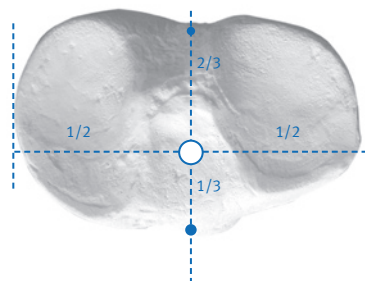


Fig. 67

Slowly insert the 1/4 in. fluted intramedullary rod to locate the medullary canal. Remove the rod and reinsert it through the preassembled intramedullary guide, which consists of the alignment guide, the saw guide, and tibial stylus (Fig. 68).

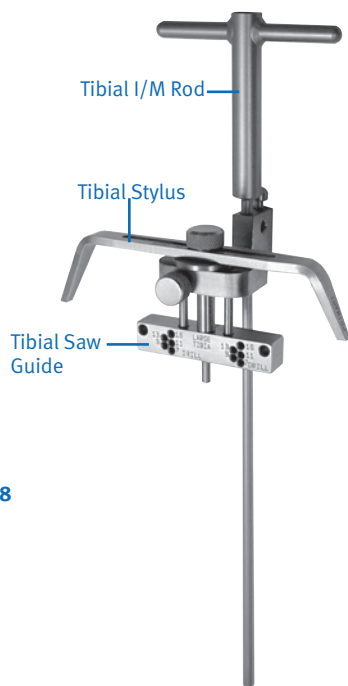

Fig. 68

Setting the Rotation

Adjust rotational alignment using the tibial tubercle. Position the distal pin of the cutting block just medial to the tibial tubercle (Fig. 69).




Fig. 69

The posterior surface of the cutting block should be parallel to the posterior edge of the tibial plateau (Fig. 70).




Fig. 70

Ideally, use both references mentioned above. Lock rotation into place by impacting the set pin with a mallet (Fig. 71). Additional stability can be obtained, if necessary, by drilling and pinning through the auxiliary hole located anteriorly.

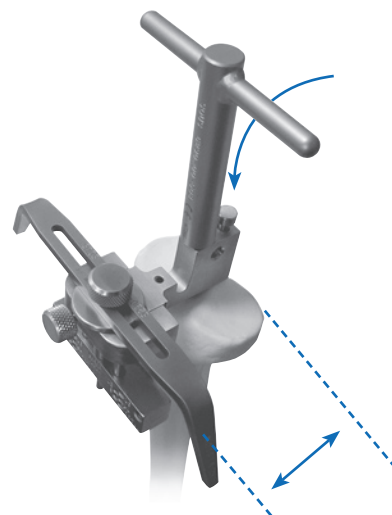


Fig. 71

Setting the Posterior Slope

Place a 5 in. x 1/8 in. pin through the 16mm hole on the cutting guide over the least-affected plateau to achieve replication. Adjust the thumb screw on the anterior side of the guide until the pin touches both the anterior and posterior rims of the proximal plateau. When the desired slope has been achieved, remove the 5 in. x 1/8 in. pin (Fig. 72).



Fig. 72

The posterior slope is set at 5° when the black line on either side of the fixed part of the guide is parallel with the posterior aspect of the swivel part of the guide (Fig. 73).



Fig. 73

Setting the Level of Resection

Place the stylus end marked “PRIMARY” over the least-involved weight bearing portion of the tibial plateau to re-create the joint line.

Stabilize the cutting guide by drilling and pinning through the 7mm medial and lateral holes of the cutting guide (Fig. 74).




Fig. 74

Remove the stylus and intramedullary rod to disassemble the jig (Fig. 75). A slaphammer helps to remove the intramedullary rod and jig, leaving the saw guide fixed to the anterior face of the tibia.




Fig. 75

Using the Tibial Spacer Option

Preparing the Tibia

Tibial spacers address medial and lateral tibial defects (and both 4mm and 8mm modular spacers are available).

Bony defects greater than 9mm of the medial or lateral tibial plateau require a minimum 9mm osteotomy. Tibial spacers correct the deformity without requiring additional bone resection.

After standard preparation of the proximal tibia, assemble the spacer cutting guide and alignment plate for sizes 00 and 0, sizes 1 and 2, or sizes 3, 4 and 5 tibias. Set the assembly for medial or lateral and left or right using the reference marks on the end of the spacer alignment plate (Fig. 76).




Fig. 76

Stabilize the alignment plate using three smooth pins placed in the nondefective tibial plateau surface previously drilled with the Proximal Tibial Drill Guide. For added stability, place at least one pin through one of the holes located anteriorly on the Spacer Cutting Guide (Fig. 77).




Fig. 77

Make a vertical osteotomy using a calibrated 1 in. saw blade (Fig. 78). This saw cut is either 4 or 8mm deep, depending on the size of the defect. Leave a free saw blade imbedded in the bone to avoid undercutting the uninvolved tibial plateau surface when the horizontal osteotomy is performed.




Fig. 78

The horizontal portion of the step cut is then made through the 4 or 8mm slot, depending on the size of the defect (Fig. 79).




Fig. 79

Trialing the Tibia

Assemble and insert the trial spacer and the trial tibial baseplate (Fig. 80). Select the tibial trial insert based on flexion and extension stability and the measured thickness of the tibial wafer of bone.

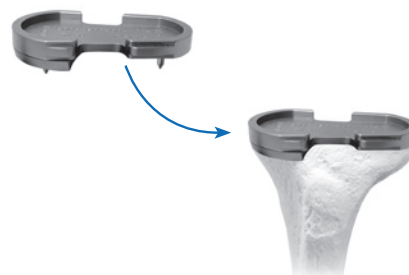

Fig. 80

Implanting the Tibia

Secure the metal spacer implant (4 or 8mm) to the underside of the final prosthetic tibial metal baseplate using a threaded peg-and-screw combination, or methyl-methacrylate bone cement combined with a cancellous bone screw (Fig. 81a).

Place the composite on the prepared surface of the tibia and secure it in place. Use a 50mm Titanium Cancellous Bone Screw in the nondefective side (Fig. 81b), which provides excellent cement pressurization.

Note: The tibial spacers may not be used with an all-poly tibia.

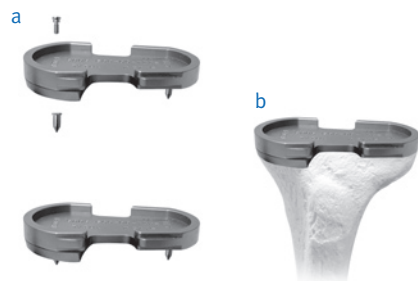


Fig. 81

All-Poly Tibial Option

Preparing the Tibia

The all-poly tibial components (congruent and ultracongruent) require distinct broaches for preparation of the cruciate stem. Insert the appropriately-sized broach into the proximal tibial sizer drill guide and fully drive it into the proximal tibia with a mallet.

There are three different size broaches: one for sizes 00 and 0, one for sizes 1 and 2, and one for sizes 3, 4, and 5 all-poly tibial components (Fig. 82). These broaches provide for a 1.5mm cement mantle around the stem.



Fig. 82

Implanting the Tibia

Cement the all-poly tibia into place using the all-poly tibia impactor (Fig. 83).



Fig. 83

Anterior Referencing Option

Preparing the Proximal Tibia

Prepare the proximal tibia as shown on pages 22-31. Accurate tibia preparation is critical, as all femoral cuts are based on the cut tibial platform.

Balancing the Soft Tissue

Balance the joint after tibial preparation. Some minor balancing can be performed during femoral preparation, but major releases should be made prior to the femoral cuts. See pages 31&32 for more detailed varus and valgus deformity correction techniques.

External Rotation of the Femur

To set the external rotation of the femur, three anatomical points are referenced:

- 1) Cut surface of the tibia
- 2) Transepicondylar axis
 - a) Laterally, mark the high spot of the epicondyle by removing the synovium from this area. The lateral epicondyle is a discrete point at the center of the lateral collateral ligament attachment.
 - b) Medially, look for the sulcus by removing the synovium from the medial collateral ligament attachment to the femur. Mark a half moon around the sulcus and pick the center point of the full circle.¹⁸
 - c) Using a flat device, draw a line between these two points using methylene blue. Use this line to reference the relative difference between the amount to be resected between the two posterior condyles. One condyle usually has a slightly larger resection level, showing 3° of external rotation.
- 3) Whiteside's line
 - a) Mark Whiteside's Line, which is typically perpendicular to the tibia and transepicondylar axis.

Locating the Medullary Canal

Locate the medullary canal as shown on page 11.

18. Berger RA, Rubash HE, Seel MJ, Thompson WH, Crossett LS. Determining the rotational alignment of the femoral component in total knee arthroplasty using the epicondylar axis. Clin Orthop. 1993 Jan; (286): 40-7.

Cutting the Preliminary Anterior Cortex

To set the anterior referencing Rotational Alignment Guide for left or right, loosen the jack screws on the block that holds the t-handle. Slide the block off the two posts attached to the stylus and rotate block 180 degrees. Slide the block back on the posts and secure with the two jack screws. A right-side-up "L" or "R" indicates the selected side (Fig. 84a).



Fig. 84a

Slide the 5/16 in. rod through the alignment guide (Fig. 84b) and place the rod into the intramedullary canal.




Fig. 84b

Place the handles on the Rotational Alignment Guide (Fig. 85).




Fig. 85

Using the handles, pull up on the Rotational Alignment Guide moving the femur superiorly to tighten the ligaments. Rotate the Rotational Alignment Guide aligning the posterior edge of the block parallel to the cut tibia plateau (Fig. 86). The marked transepicondylar axis should be parallel to the posterior edge of the block and the tibial plateau.

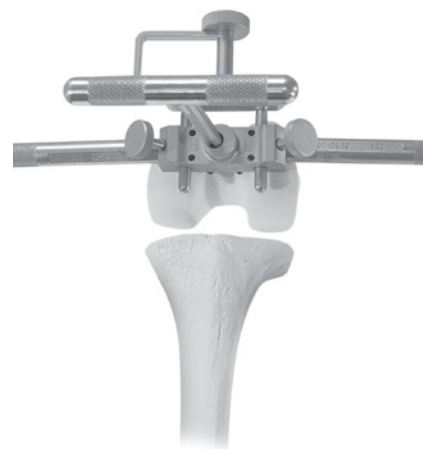


Fig. 86

Once the rotation guide is set, drill and pin the medial side, then the lateral (Fig. 87). Remove the handles.




Fig. 87

Turn and place the stylus on top of the anterior femur (Fig. 88). Place an angelwing through the Rotational Alignment Guide saw slot to check the resection level. The guide is intended to take a small button of bone off both anterior condyles. Lock the saw slot in place by tightening the two jackscrews.

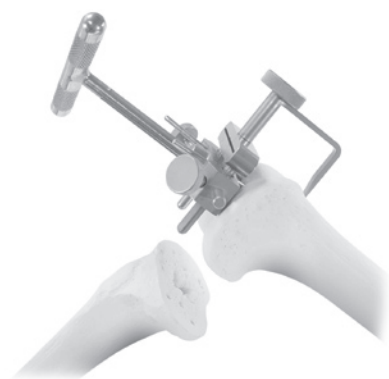

Fig. 88

Cut through the slot (.060 in. slot) in the Rotational Alignment Guide to make your preliminary cut of the anterior cortex (Fig. 89).



Fig. 89

Remove the T-handle. Use the pin puller to remove both pins. Remove the Rotational Alignment Guide.

Cutting the Distal Femur

See pages 10-12 for making the distal femoral cuts.

Calibrating the Femur

With the knee maximally flexed, center the Distal Femoral Drill Guide on the femoral condyles. With the anterior approach, the Distal Femoral Drill Guide is used only to determine the implant size. Do not drill the lug holes.

Position the guide by referencing the posterior femoral condyles on the skids and stabilize it by seating the two captured set pins into the distal femur (Fig. 90).




Fig. 90

The Distal Femoral Drill Guide acts as a caliper to determine the correct anterior/posterior femoral size (Fig. 91). If the mark falls between sizes, the smaller size should be chosen to prevent excess tightness in flexion.




Fig. 91

Drilling the Distal Femoral Holes

Place the appropriately sized Anterior Referencing Femoral Drill Guide onto the femur. Each femoral drill guide matches the width of its corresponding femur. Center the block medial to lateral (Fig. 92).



Fig. 92

The guide should sit flat on the anterior cortex and rest against the cut distal femur.

The inferior edge of the Femoral Drill Guide ends where the posterior femur will be resected and should also be parallel to the cut surface of the tibia.

Drill and pin the Femoral Drill Guide if needed for stability with soft bone (Fig. 93).



Fig. 93

Use the standard 1/4 in. stop drill to make the two reference drill holes for placement of the anterior/posterior and chamfer cutting blocks (Fig. 94).



Fig. 94

Making the Anterior/Posterior and Chamfer Cuts

Once the reference holes are drilled, the rest of the procedure uses the standard technique and instruments, starting with the posterior and anterior femoral cuts. See pages 14-15 for more details.

With all femoral cuts complete, there should be a rectangular space created between the femur and tibia in both 90° of flexion and extension. The flexion and extension gaps should be equal.

Balancing the Soft Tissue

Varus Deformity

A varus deformity is easier to correct than a valgus deformity because most of the soft tissue balancing is done with the usual surgical approach to the knee. When the knee is exposed and being prepared for arthroplasty, the medial soft tissue must be released back to the posteromedial corner. This usually releases enough soft tissue initially so that the cuts of the femur, tibia and patella can be made and the final soft tissue balancing can be done with the trial components. Typically, if the knee has less than 10° of varus deformity, the normal medial release done to expose the tibia is enough to correct the deformity. A slight amount of lateral laxity is acceptable since a varus knee will frequently have a stretched-out lateral soft tissue sleeve. The dynamic nature of the lateral side, including the biceps and iliotibial band, eliminates any clinical consequence.

With the posterior cruciate ligament (PCL) intact, the knee should come to full extension. Check this by placing a hand on the greater trochanter. Medial/lateral stability in full extension should have 1mm of laxity. The normal knee has 7° of varus/valgus play. Always test the competence of the PCL by performing a forced posterior draw maneuver. If excessive femoral roll-back in flexion is present, the PCL should be progressively released from the tibia.

In the case of a varus knee that has a significant flexion contracture (greater than 15°), the PCL most likely will require resection. If the PCL is resected, the knee is balanced so that the collateral ligaments have no laxity and the knee rests with 5° to 10° of spring short of full extension. One size/thickness larger tibial insert than the measured amount of bone resection should be implanted. For example, if 9mm of tibia is resected, use an 11mm insert. The posterior capsule will stretch out over the first six months. If the knee lacks full extension, but excessive roll-back is not present in flexion, one can alternatively resect more distal femur (or proximal tibia) by using the +2mm, 2mm, or -4mm block (auxiliary distal femoral saw guide), rather than resecting the PCL. Approximately 1mm of bone resection is required for every 4° of contracture.

Valgus Deformity

Valgus deformities are more difficult to properly balance than varus deformities. A valgus deformity frequently has a stretched out medial collateral ligament that can be difficult to tighten. In many cases it will be easier to balance between medial and lateral if the PCL is resected.

This will allow overstuffing the joint by one insert thickness, which will slightly tighten the medial side. Valgus knees are a frequent indication for use of the ultracongruent or traditional PCL substituting (PS) components, which provide increased anterior/posterior stability as well as rotational stability. Alternatively, if there is greater than 1cm of difference between varus and valgus laxity, the superficial medial collateral ligament should be advanced distally on the tibia and stabilized with a ligament staple.

Perform lateral soft tissue releases in the following sequence: the popliteus tendon is taken at the time the lateral meniscus is removed. While removing posterior osteophytes, the posterior capsule is released from the femur, which should help with posterolateral tightness. The trials are then placed and the other lateral structure palpated for tightness. If the knee is tight laterally in extension and not flexion, this is due to a tight iliotibial band. The iliotibial band is released from the inside by simply feeling the tight portion of the iliotibial band and transversely sectioning it with a knife while the knee is in full extension. If care is taken to keep all of the release anterior to the head of the fibula, the peroneal nerve should be well protected.

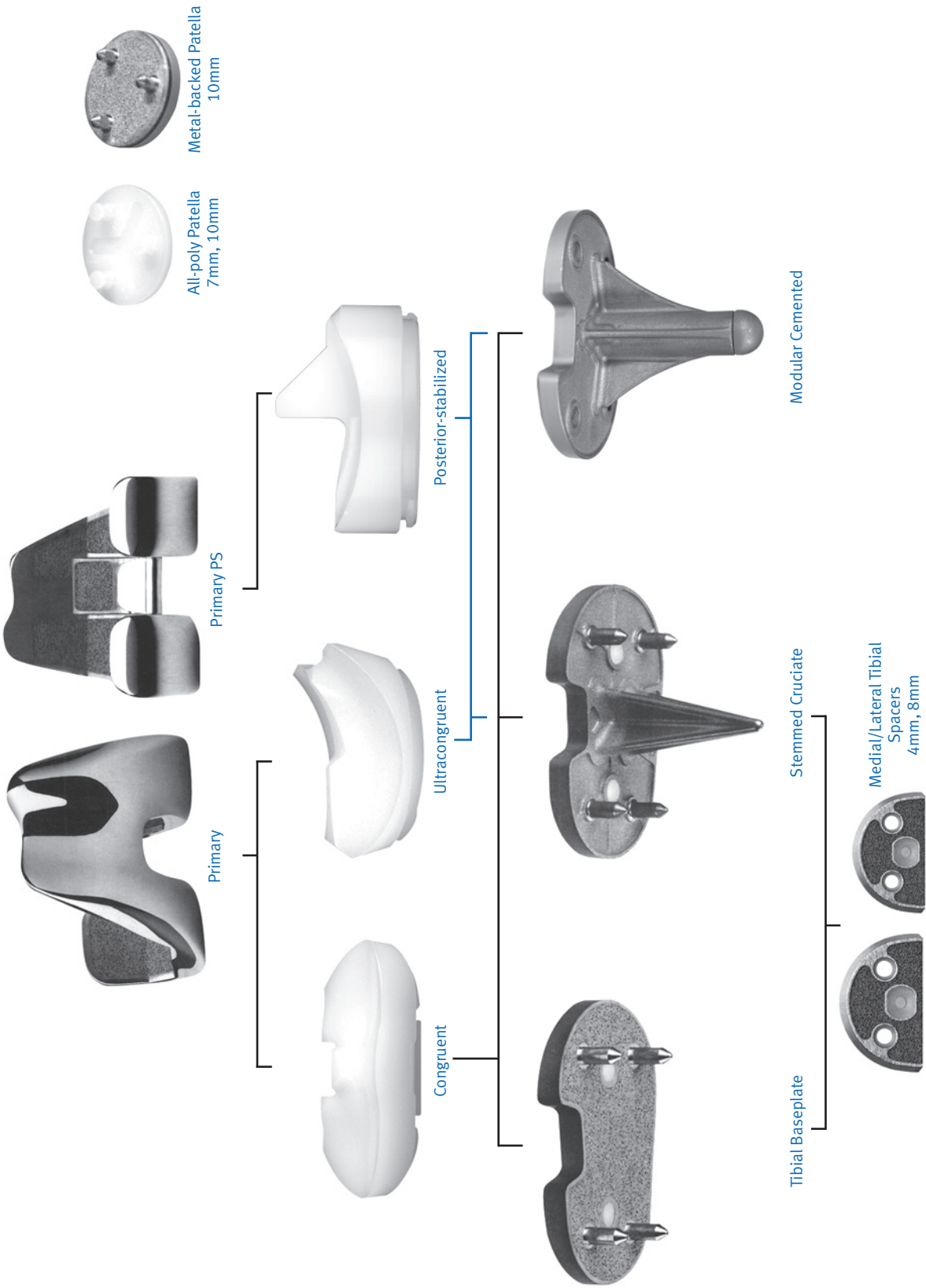
If the knee is tight in both extension and flexion, the lateral collateral ligament is usually tight. This can be confirmed by placing a finger in the lateral gutter of the knee and palpating the lateral collateral ligament to determine if it is too tight. With the knee in flexion, release the lateral collateral ligament flexion by peeling the lateral collateral ligament subperiosteally off its origin on the femur to allow it to slide distally. The lateral collateral ligament can be released partially or completely in continuity with the lateral posterior capsule. Another option is to do a Z-lengthening of the fibular collateral or the iliotibial band. In extreme cases of valgus deformity, the biceps tendon may need to be released through a separate incision.

Ultracongruent and Traditional Posterior Stabilized Component Indications

1. Marked valgus deformity - requiring PCL and lateral soft tissue release.
2. Prior high tibial osteotomies - soft tissue balancing is the same as for a valgus deformity with lateral soft tissue and PCL release.
3. Patellectomy - PCL incomplete or absent.
4. Most revision situations - PCL deficient or nonfunctional.

Note: The ultracongruent insert and traditional posterior stabilized components are contraindicated if the PCL is present.

Natural-Knee II Primary System





Contact your Zimmer representative or visit us at www.zimmer.com



+H124976299002001/\$051109R1G090

97-6299-002-00 Rev. 1 2.5ML Printed in USA ©2005, 2009 Zimmer, Inc.